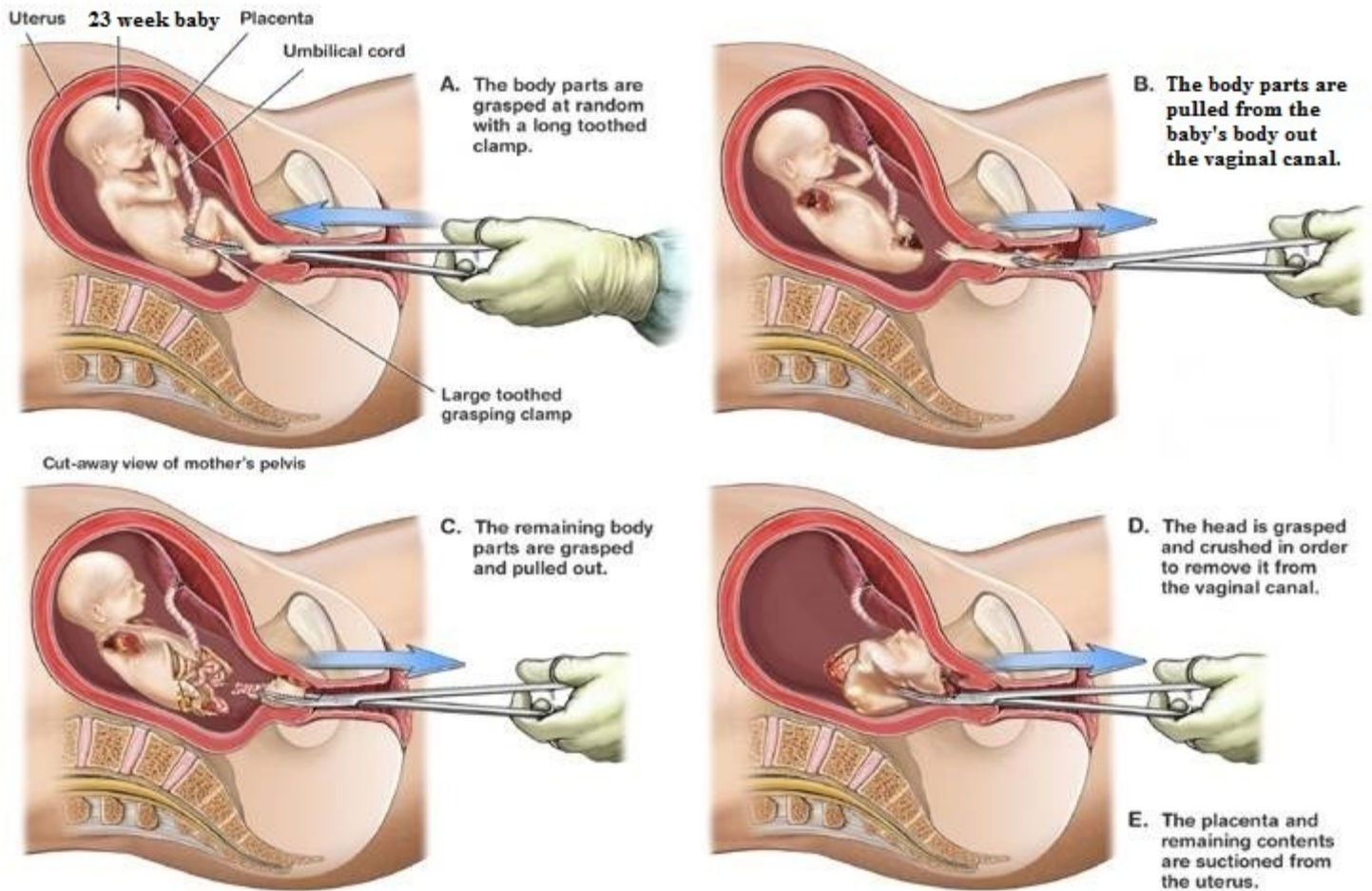
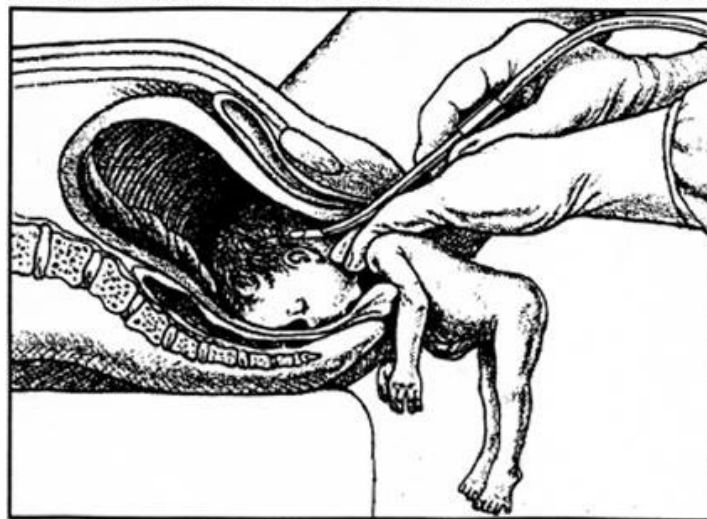


## Dilation and Evacuation Abortion (D&E) of a 23 Week Old Baby

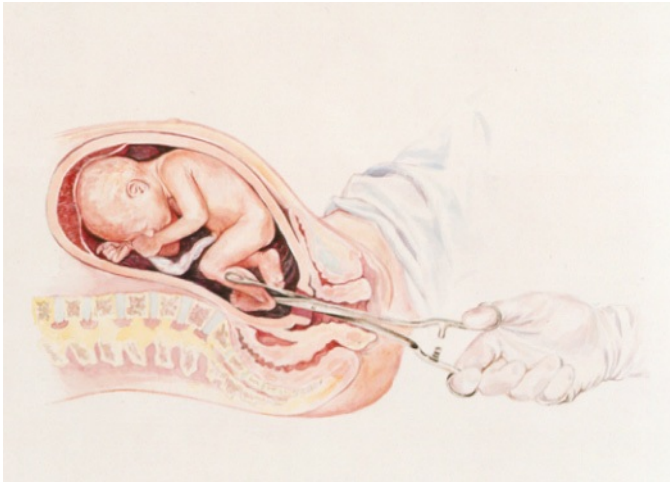

### Late Second and Third Trimester Partial Birth Abortion

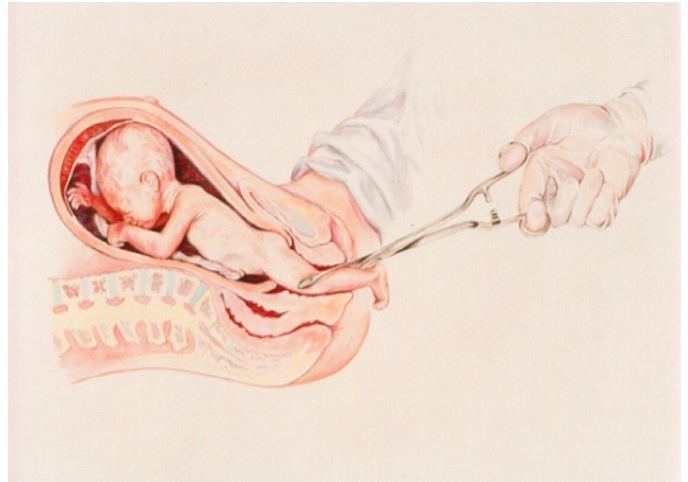


*The abortionist pulls the baby into the breech position. He forces scissors into the skull, removes them and inserts a suction catheter through which he sucks the baby's brains out.*

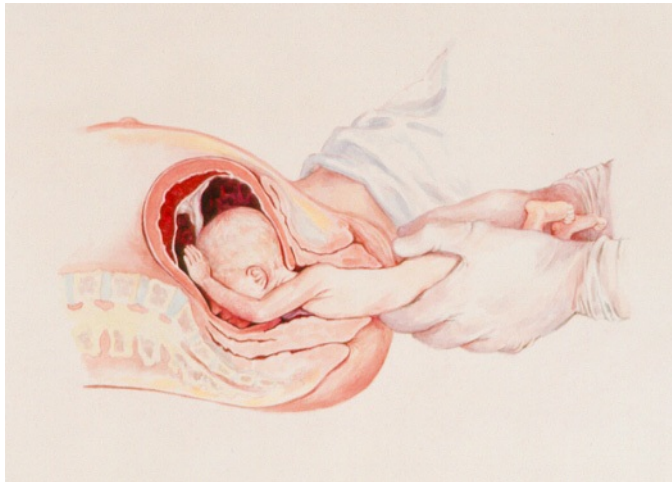## PARTIAL BIRTH ABORTION TORTURE



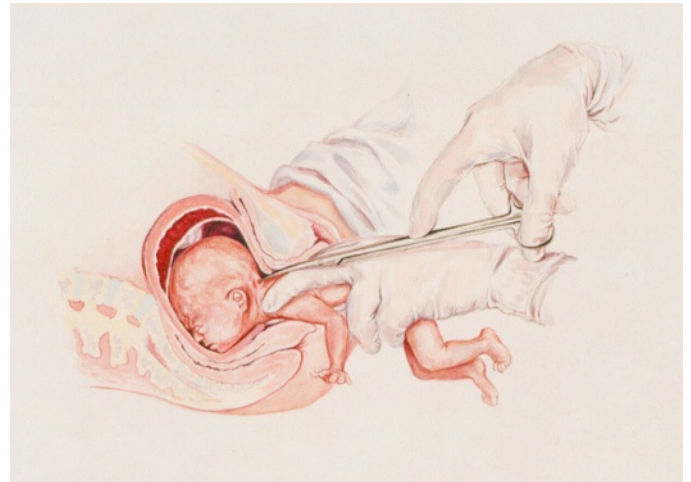**Step 1: Guided by ultrasound, the abortionist grabs the baby's leg with forceps.**



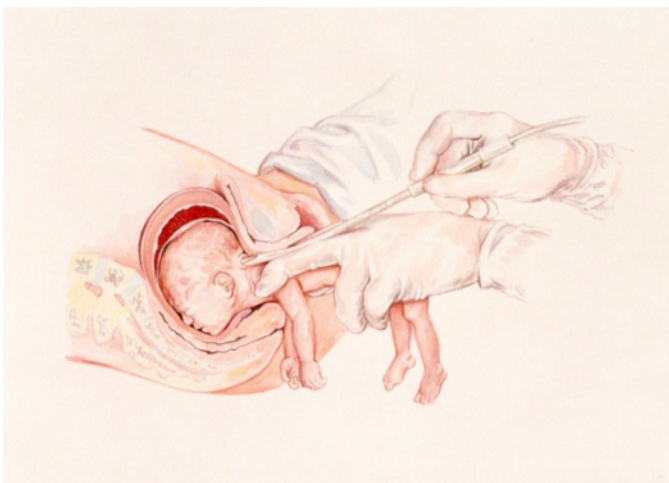**Step 2: The baby's leg is pulled out into the birth canal.**



**Step 3: The abortionist delivers the baby's entire body, except for the head.**

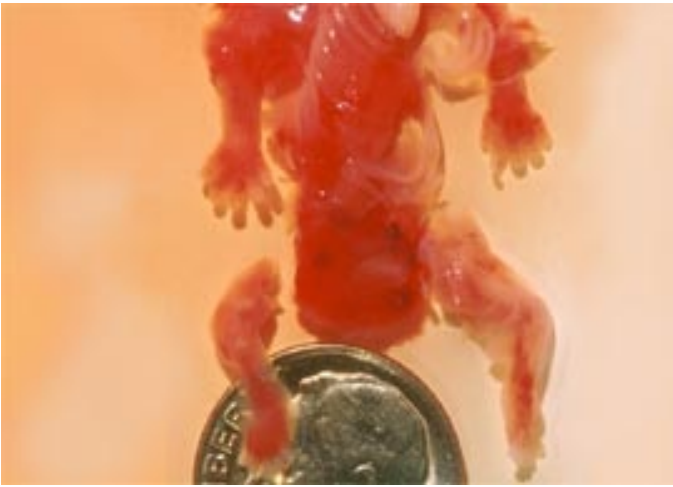

**Step 4: The abortionist jams scissors into the baby's skull. The scissors are then opened to enlarge the hole.**

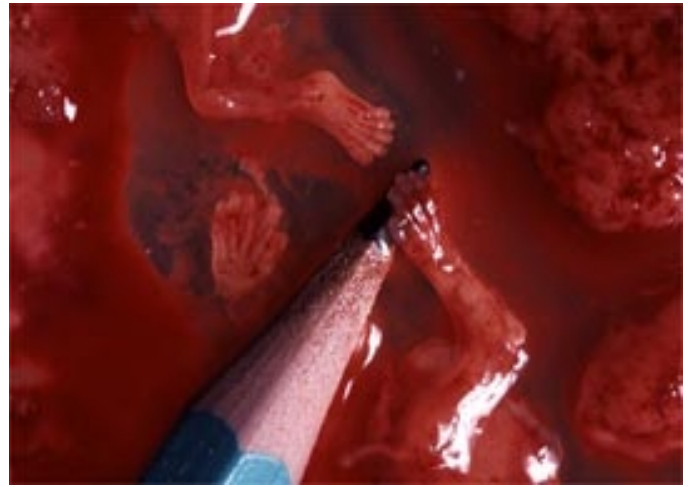

**Step 5: The scissors are removed and a suction catheter is inserted. The child's brains are sucked out, causing the skull to collapse. The dead baby is then removed.**

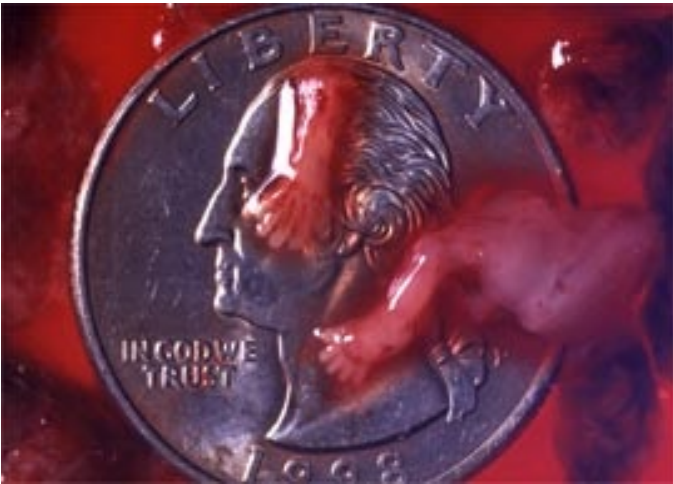



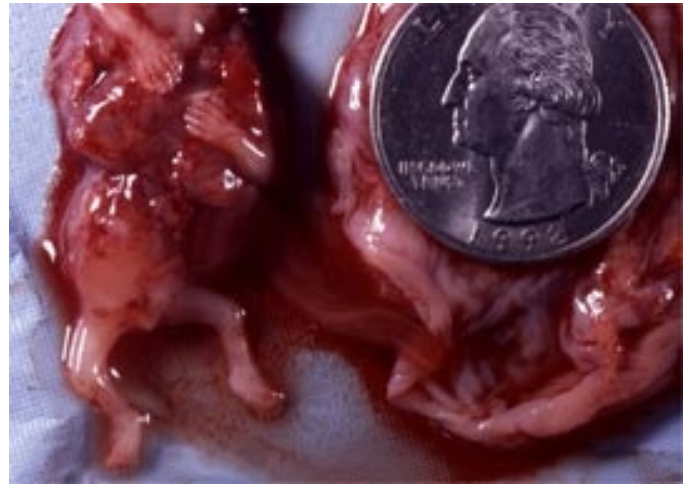**ABORTED 1<sup>ST</sup> TRIMESTER: 7 WEEKS**



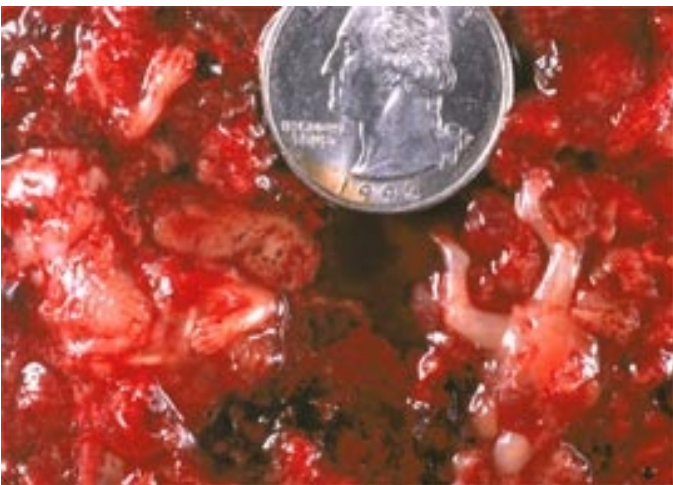
**ABORTED 1<sup>ST</sup> TRIMESTER: 8 WEEKS**



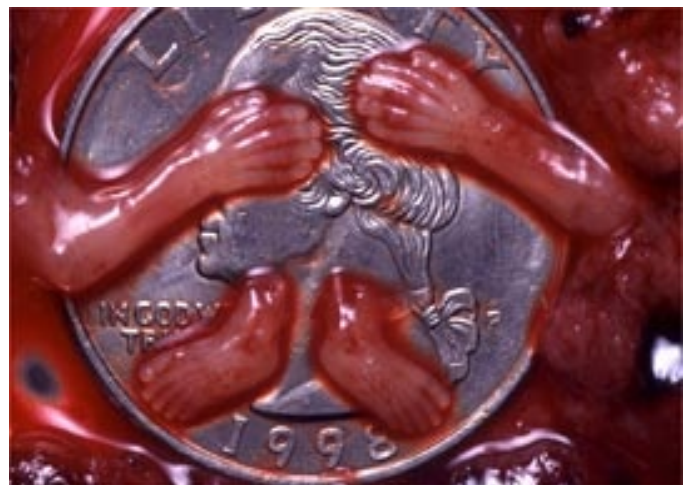**ABORTED 1<sup>ST</sup> TRIMESTER: 8 WEEKS**



**ABORTED 1<sup>ST</sup> TRIMESTER: 8 WEEKS**

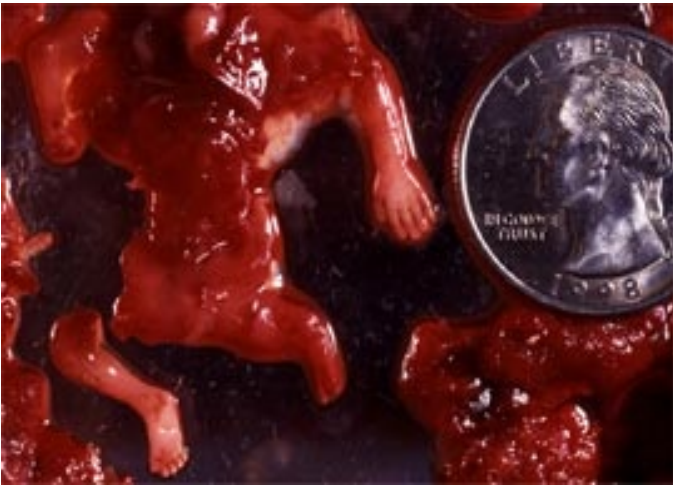

**ABORTED 1<sup>ST</sup> TRIMESTER: 8 WEEKS**

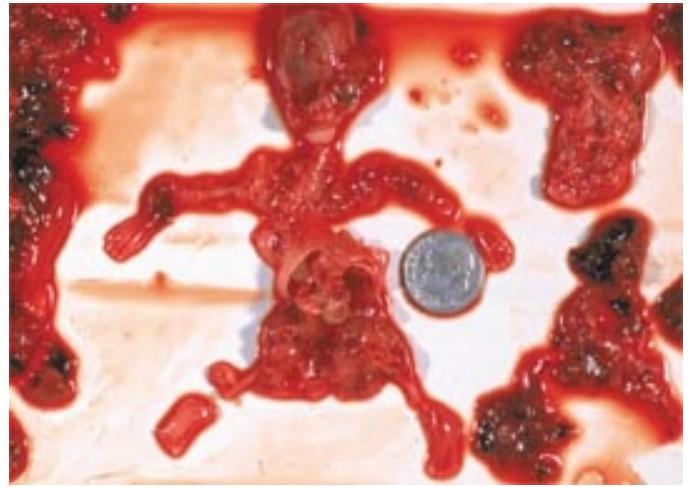


**ABORTED 1<sup>ST</sup> TRIMESTER: 9 WEEKS**

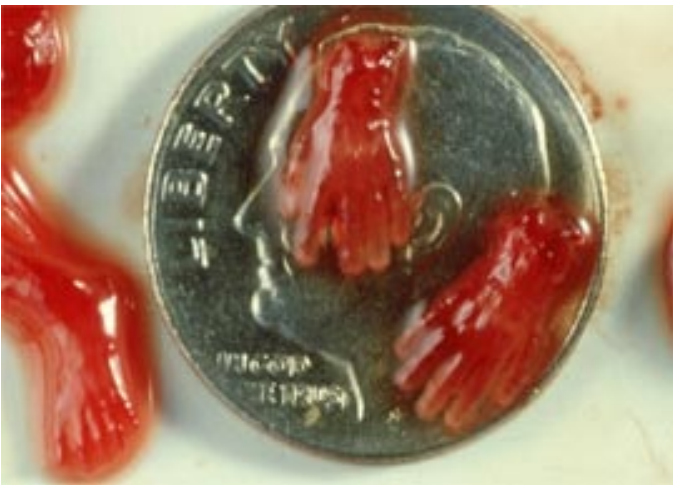




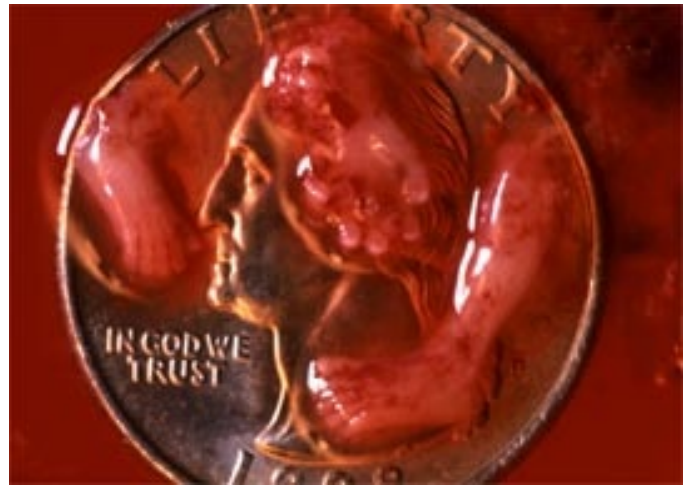**ABORTED 1<sup>ST</sup> TRIMESTER: 9 WEEKS**



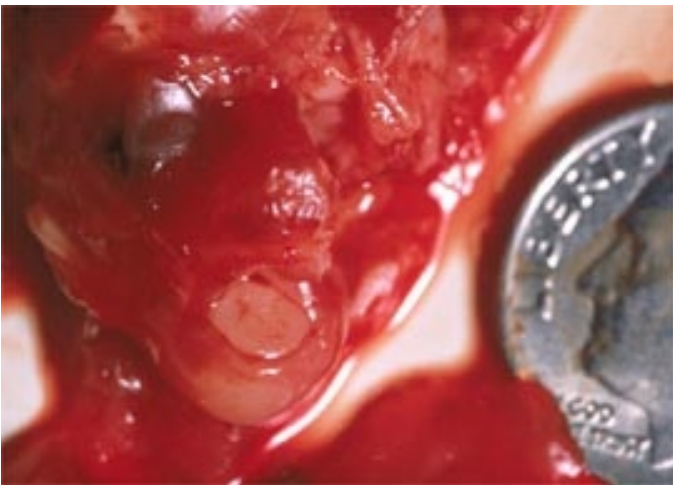
**ABORTED 1<sup>ST</sup> TRIMESTER: 9 WEEKS**



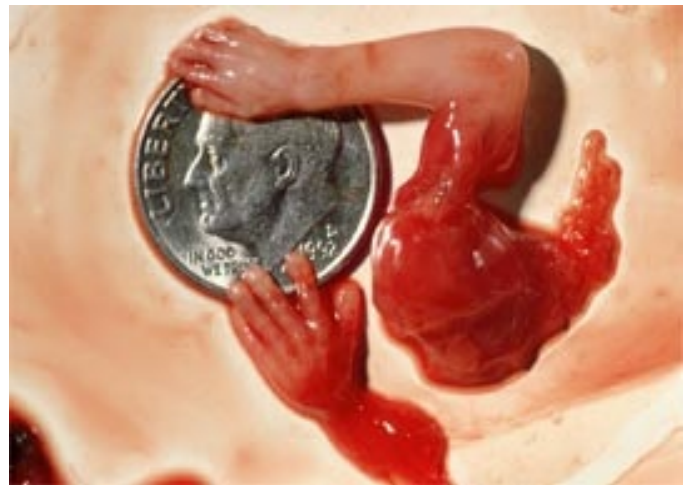**ABORTED 1<sup>ST</sup> TRIMESTER: 9 WEEKS**



**ABORTED 1<sup>ST</sup> TRIMESTER: 9 WEEKS**

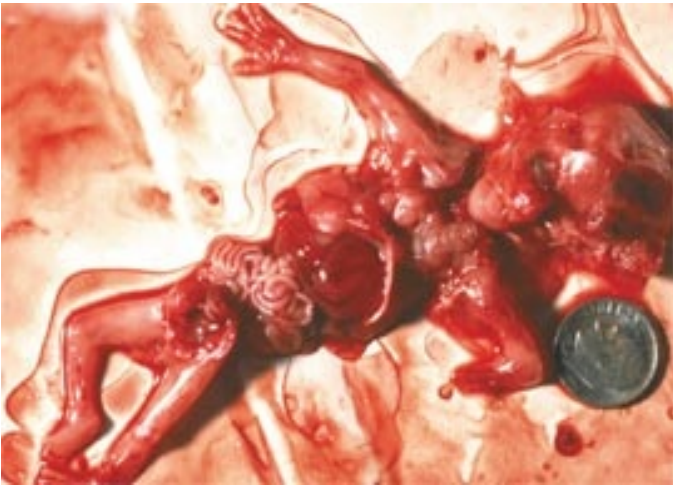

**ABORTED 1<sup>ST</sup> TRIMESTER: 10 WEEKS**

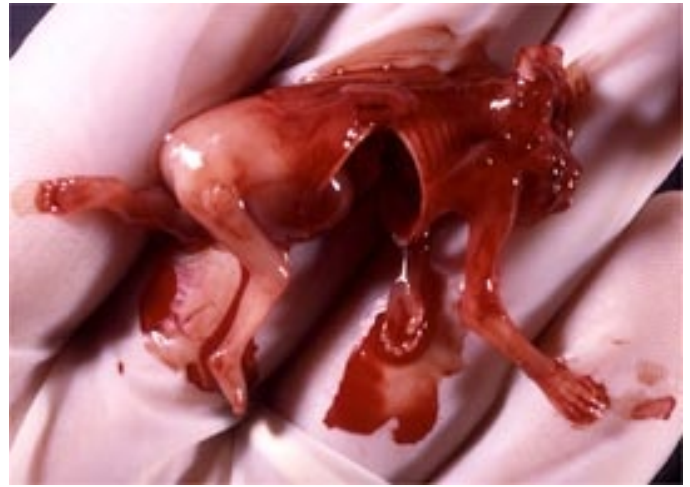

**ABORTED 1<sup>ST</sup> TRIMESTER: 10 WEEKS**

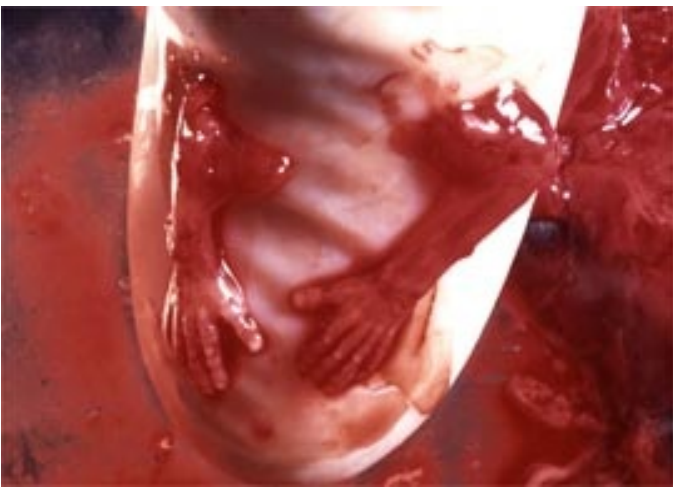




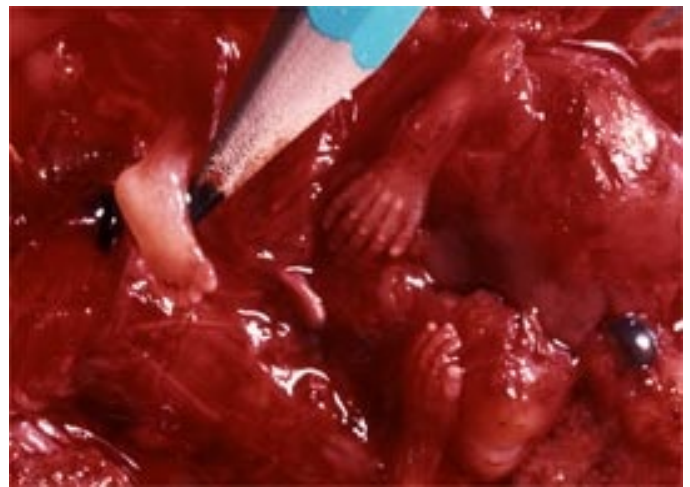
**ABORTED 1<sup>ST</sup> TRIMESTER: 10 WEEKS**



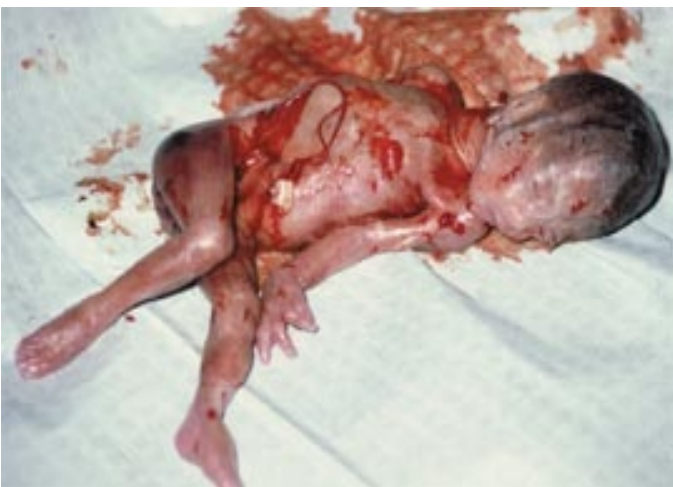**ABORTED 1<sup>ST</sup> TRIMESTER: 11 WEEKS**



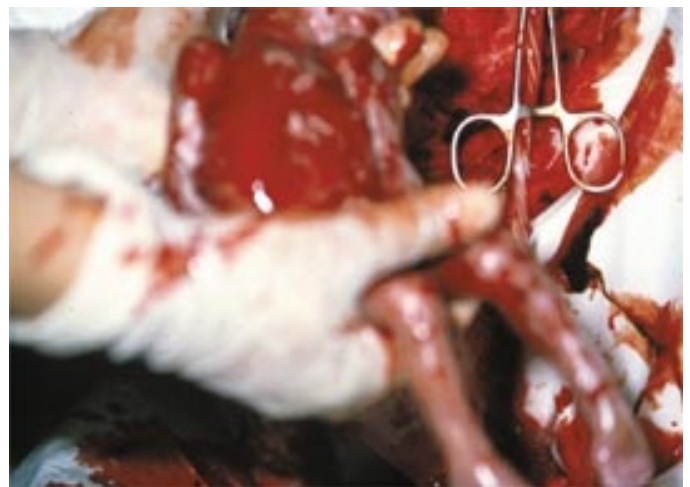**ABORTED 1<sup>ST</sup> TRIMESTER: 11 WEEKS**



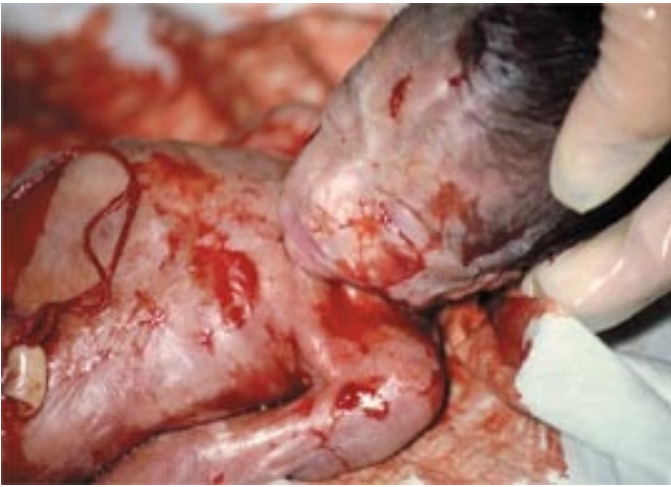**ABORTED 1<sup>ST</sup> TRIMESTER: 11 WEEKS**



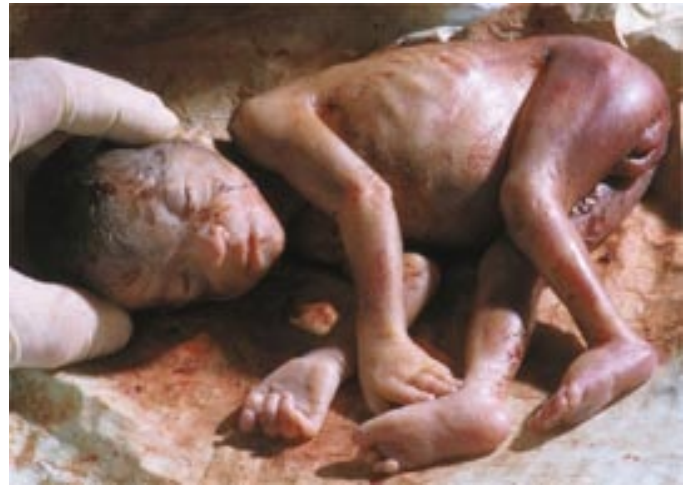**ABORTED 2<sup>ND</sup> TRIMESTER: 22 WEEKS**



**ABORTED 2<sup>ND</sup> TRIMESTER: 22 WEEKS**

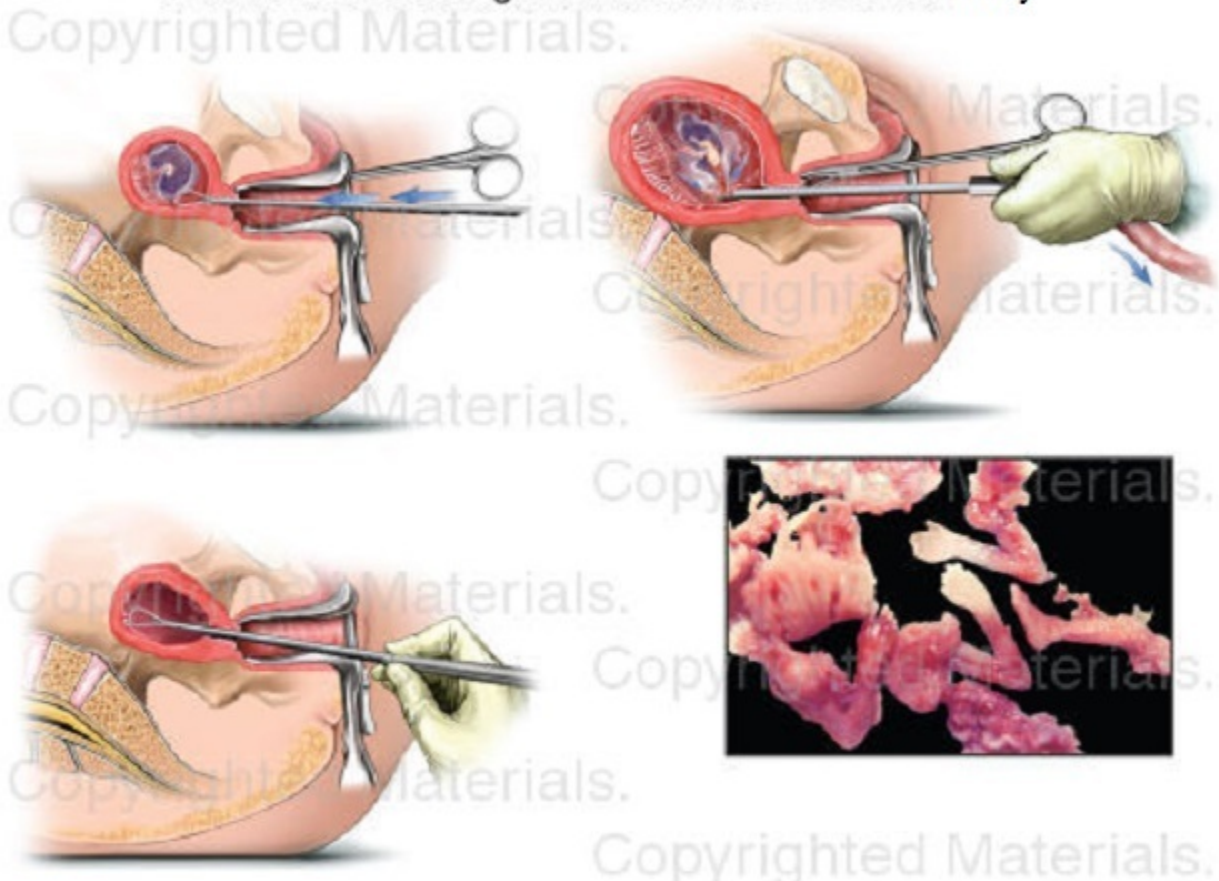


**ABORTED 2<sup>ND</sup> TRIMESTER: 22 WEEKS**



**ABORTED 2<sup>ND</sup> TRIMESTER: 24 WEEKS**

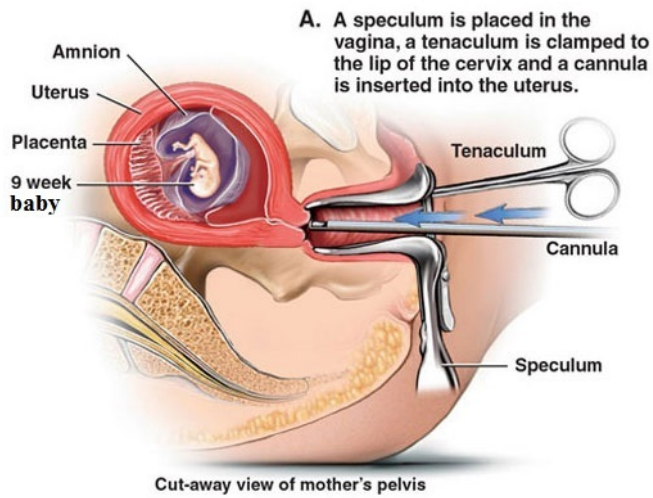
### Suction and Curettage Abortion of a 9 Week Old Baby



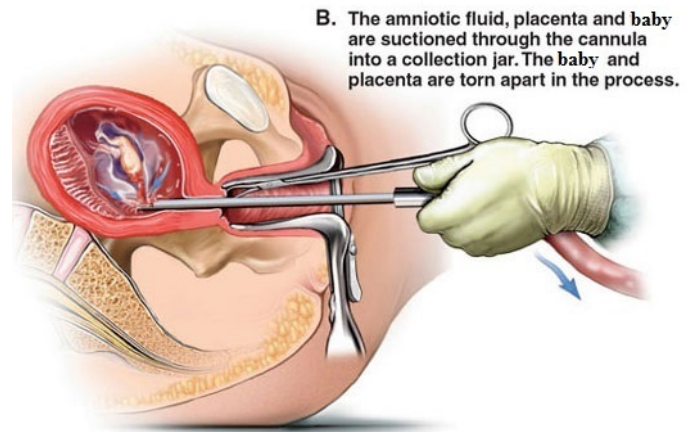
**Note The Baby's Ripped Apart Body Parts On The Inset Picture.**



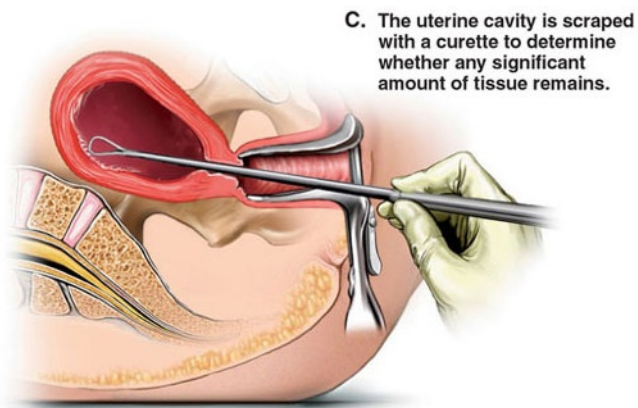
## DETAILS OF SUCTION CURETTAGE OR VACUUM ASPIRATION ABORTION AT 9 WEEKS



**STEP 1**



**STEP 2**



**STEP 3**